

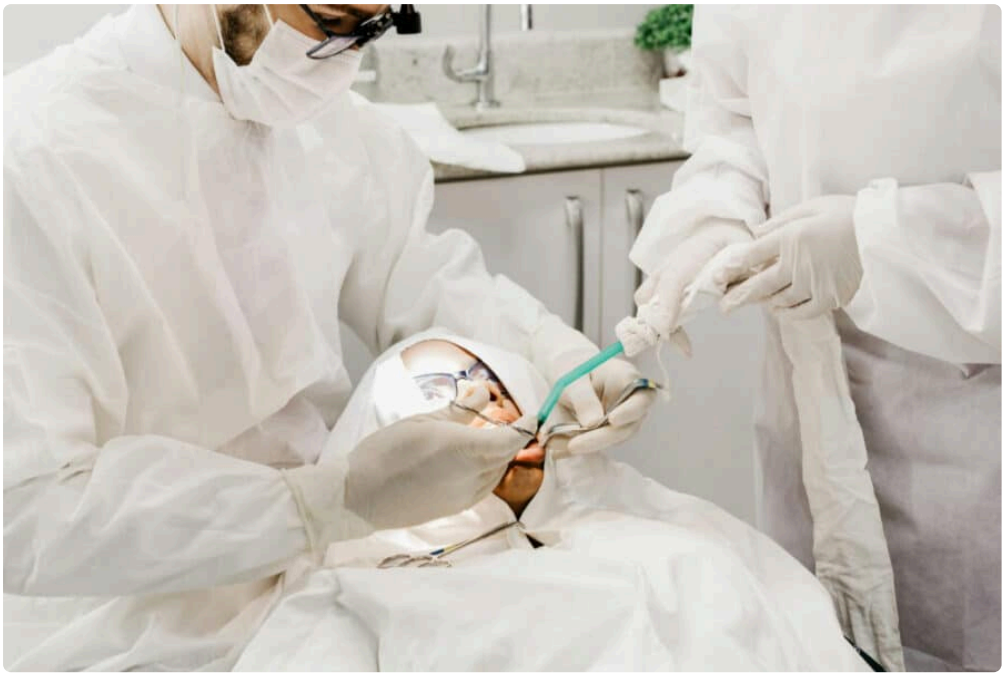

Accidents rarely arrive at a convenient time. A fall on the stairs, a collision during a weekend football match, a child taking an elbow to the mouth at school, a cycling spill on the way to work, these moments can change the condition of a tooth in seconds. What often catches people off guard is how quickly a dental injury becomes more than a cosmetic problem. Pain can escalate, bleeding can persist, nerves can be exposed, and the window to save a damaged tooth can narrow fast.

That is why an Emergency Dentist matters so much after an accident. The role is not simply to “fix a tooth.” It is to assess hidden damage, control pain, protect the surrounding tissues, and make decisions under time pressure that can affect oral health for years. People tend to recognize a medical emergency when they see heavy bleeding or a broken bone. Dental trauma deserves the same urgency. In practice, some of the most preventable long-term dental problems begin when someone assumes they can wait until Monday.

A dental injury is often more serious than it looks

One of the difficult realities of mouth injuries is that they can be deceptive. A tooth may appear only slightly chipped while the root has been compromised. Lips and gums can swell enough to conceal a fracture line. Teeth can become loosened without falling out. A patient may say, “It doesn’t hurt that much,” only to discover hours later that the nerve has been traumatised or the bite no longer fits properly.

I have seen patients arrive after a sports injury convinced that they only needed a small filling because the front tooth looked uneven. On examination, the tooth had actually shifted position and the supporting ligament had been injured. Without prompt care, that kind of trauma can lead to pulp damage, infection, or even tooth loss. The visible part of the injury is only one piece of the picture.

The mouth also contains structures that work together closely. A blow that cracks one tooth may bruise the jaw joint, split the gum, damage neighboring teeth, or create a bite imbalance that causes headaches and chewing pain later. A general sense of “I hit my mouth” does not provide enough information. A proper trauma assessment does.

Time changes the outcome

When someone seeks emergency dental care quickly, the dentist has more options. That matters in cases involving knocked-out teeth, displaced teeth, fractures that expose the nerve, or deep cuts to the soft tissues. Delay can mean contamination, dehydration of the tooth root, swelling, clot formation in the wrong place, and a lower chance of preserving the natural tooth.

A knocked-out permanent tooth is the clearest example. The best outcomes often happen when reimplantation is attempted as soon as possible, ideally within 30 to 60 minutes. That is not a guarantee, but it is a useful benchmark. People sometimes waste precious time searching online, calling multiple clinics, or waiting to “see how it feels.” In that same hour, the root surface can dry out and the prognosis can worsen significantly.

Timing also affects pain control. A cracked tooth left untreated after an accident can become exquisitely sensitive to air, water, and pressure. What starts as discomfort can turn into throbbing pain by nightfall. Early treatment may involve simple stabilisation or protective covering. Late treatment may require more invasive work because the injury had time to progress.

What an Emergency Dentist can do that waiting cannot

An Emergency Dentist is trained to manage urgent dental trauma in a structured way. The value lies in both speed and judgment. It is not just about seeing a patient the same day. It is about knowing which injuries require immediate intervention, which can be stabilized and reviewed, and which signs suggest deeper complications.

After an accident, a proper emergency dental visit usually includes a close clinical exam, checks for mobility and bite changes, assessment of soft tissue wounds, and imaging where appropriate. X-rays can reveal root fractures, displacement, injuries to the surrounding bone, and foreign material embedded in the lip or gum. Those findings are easy to miss without equipment and experience.

Treatment may include repositioning a tooth, splinting loose teeth, smoothing sharp edges, protecting exposed dentine, placing a temporary or definitive restoration, suturing soft tissue injuries, prescribing medication when clinically indicated, and coordinating follow-up for pulp testing or specialist care. Just as important, the dentist documents baseline findings. If the tooth later changes color, loses vitality, or develops symptoms, there is a clear record of the initial trauma.

This is where waiting becomes risky. People often think the choice is between “fix it now” and “fix it later.” In truth, the real choice is often between preserving options now or dealing with fewer, more expensive, more

complex options later.

The first hour after an accident

The period immediately after a mouth injury is often chaotic. Someone is shaken up, bleeding, embarrassed, or trying to comfort a child. Calm, practical steps can make a meaningful difference before the patient reaches an Emergency Dentist.

- Control bleeding with clean gauze or cloth and gentle pressure.
- If a permanent tooth is knocked out, handle it by the crown, not the root, and keep it moist in milk or saliva if it cannot be placed back immediately.
- Use a cold compress on the outside of the face to limit swelling.
- Save broken tooth fragments if you can find them.
- Seek urgent dental assessment, especially for loose, displaced, broken, or missing teeth.

Those steps are not a substitute for treatment, but they can protect the injury from getting worse. One important nuance is age. If a baby tooth is knocked out, it is generally not replanted because doing so can harm the developing permanent tooth underneath. That is exactly the kind of distinction that makes quick professional advice so valuable.

Pain is only one part of the story

Many people judge urgency by pain level. That can be misleading. Some severe injuries hurt surprisingly little at first because adrenaline masks symptoms. Others are intensely painful but structurally less serious. An Emergency Dentist looks beyond discomfort and focuses on tissue damage, contamination, stability, and blood supply.

A tooth that has been intruded, meaning pushed upward into the socket, may not be the most painful injury in the room, yet it is a serious trauma. A cracked cusp may feel dramatic because the edge is sharp and the cold sensitivity is immediate, but the long-term outlook can be very good if treated promptly. The human nervous system does not rank dental injuries accurately on its own.

This becomes especially important with children and teenagers. Younger patients may struggle to describe what they feel. They may say “my tooth is funny” rather than “my bite is off” or “the tooth is mobile.” They may also focus on lip swelling while ignoring a tooth that has shifted position. An experienced emergency clinician knows how to assess those details without relying entirely on the patient’s description.

Saving the natural tooth is usually the best outcome

Dentistry offers excellent restorative options, but there is still no perfect substitute for an intact natural tooth. Implants, bridges, crowns, and root canal treated teeth all have their place, and sometimes they are necessary. Still, if an accident creates a realistic chance to save the original tooth, that chance is worth pursuing promptly.

Natural teeth have living support structures, subtle movement, and a biological relationship with the surrounding bone and gum tissue that prosthetic replacements cannot fully duplicate. Preserving them helps maintain function, appearance, and often cost control over the long term. Emergency care is often what keeps that possibility alive.

Consider the common case of a tooth that has been loosened but not fully avulsed. If it is repositioned and stabilised quickly, healing may proceed well with close monitoring. If the patient waits several days because “it

wasn't that bad," the tooth may move further out of alignment, the bite may traumatize it repeatedly, and the pulp may deteriorate. The eventual treatment may shift from conservative management to root canal therapy, extraction, or prosthetic replacement.

Soft tissue injuries need expert attention too

People often focus on teeth because teeth are visible, but lips, cheeks, tongue, and gums can suffer substantial trauma during an accident. Small cuts can hide grit, glass, tooth fragments, or asphalt particles. A split lip may look superficial from the outside while extending deeper inside the mouth. Gum tears around a tooth can signal disruption to the supporting tissues.

An Emergency Dentist evaluates these injuries in context. If a patient bit through the lip during a fall, there is a real possibility that a piece of tooth is embedded in the tissue. A soft tissue X-ray may be needed. Cleaning and closure matter not only for healing but also for infection control and cosmetic outcome. Scarring at the lip line is not trivial, especially for visible injuries in young adults and children.

There is also the issue of tetanus status and broader medical concerns. Dentists do not work in isolation during trauma cases. A good emergency provider knows when a patient needs hospital assessment for suspected jaw fracture, concussion, uncontrolled bleeding, or facial injury beyond the scope of a dental clinic. Prompt referral is part of competent emergency care.

Hidden fractures and delayed complications

Some of the most frustrating dental injuries are those that seem to settle down, then create problems weeks or months later. A tooth may survive the initial impact but later develop pulp necrosis, discoloration, sensitivity, infection, or resorption. That does not mean the early emergency visit was unnecessary. Quite the opposite. Early diagnosis, proper splinting, and documented follow-up improve the chances of spotting those complications before they become severe.

Root fractures are a good example. They are not always obvious without imaging and careful testing. A patient may continue chewing on the tooth, assuming it is only bruised. The fracture can then destabilise the tooth further. Similarly, a crown fracture can expose the inner layers of the tooth enough to invite bacterial contamination even if the pain is mild.

A competent Emergency Dentist will often advise a review schedule after the first visit. Trauma care is rarely a single appointment event. It may involve observation, vitality testing, repeat X-rays, and reassessment of mobility. That ongoing plan is part of the service. The first emergency visit starts a process designed to preserve function and reduce surprises.

The financial argument for fast care

People sometimes hesitate because they worry about the cost of urgent treatment. That is understandable. Emergency appointments can feel unplanned and stressful. Yet from a practical standpoint, early intervention is often the cheaper path.

A simple protective restoration placed after a fracture may prevent a later root canal and crown. Prompt reimplantation of a knocked-out tooth may avoid years of prosthetic treatment. Early splinting of a displaced tooth may preserve it in a way that waiting cannot. Once infection, non-restorability, or bone loss enters the picture, treatment becomes more extensive and more expensive.

There is also the indirect cost. Dental pain interferes with work, sleep, school, and eating. Facial swelling can be socially and professionally disruptive. Parents may need to miss work when a child has untreated dental trauma. Fast access to an Emergency Dentist often limits both the clinical damage and the logistical fallout.

Not every accident belongs in a hospital, but some do

One point worth clarifying is where to go. Many dental injuries are best managed by an Emergency Dentist rather than a general emergency department, particularly when the issue is isolated to the teeth and gums. Hospital emergency rooms are essential for serious systemic injuries, but they may have limited resources for definitive dental treatment. They can manage pain, rule out major facial trauma, and address life-threatening concerns, but they often cannot reposition and splint a tooth or restore a fractured crown on the spot.

That said, there are situations where hospital care should come first. Loss of consciousness, suspected jaw fracture, difficulty breathing, severe facial swelling, uncontrolled bleeding, deep lacerations, or signs of head injury change the priority. In those cases, stabilising the patient medically takes precedence. Dental treatment follows once urgent medical risks are addressed.

Judgment matters here. The best emergency clinicians, medical or dental, recognize the limits of their setting and act accordingly.

Children, sports, and the accidents that happen most

A large share of dental trauma comes from ordinary life rather than dramatic events. Children trip on playground equipment. Teenagers collide during basketball. Adults crack a tooth in a cycling fall or while rushing down icy steps. Front teeth are frequent victims because they take the brunt of the impact.

Sports injuries deserve special mention because many are preventable and many become worse when players try to finish the game before seeking care. A custom or well-fitted mouthguard reduces risk, but it does not eliminate it. When a player takes a smyledentist.com Emergency Dentist blow to the mouth and says, “I can still play,” that is not reassurance. It may just mean the damage has not declared itself fully yet.

Parents often face a difficult call after a child’s accident because baby teeth and permanent teeth behave differently. A dentist can distinguish between normal post-injury tenderness and signs that a permanent successor may be affected. That guidance is hard to improvise at home.

What to expect at the appointment

Patients are often calmer when they know what will happen. Emergency dental care after an accident is usually methodical rather than dramatic. The dentist will ask how the injury happened, when it occurred, whether there was loss of consciousness, what symptoms have appeared, and whether the tooth was stored properly if it came out. Then comes the exam, with attention to the teeth, gums, bite, lips, tongue, and sometimes the jaw joint.

Imaging is common because trauma does not always show itself on the surface. The immediate treatment plan depends on what those findings reveal. In some cases, the goal is definitive repair that day. In others, the priority is stabilisation, pain control, and close review once swelling decreases. Good emergency care is not rushed dentistry. It is focused dentistry.

Patients sometimes expect the dentist to know instantly whether a traumatised tooth will “be fine.” That certainty is not always possible on day one. Teeth can behave unpredictably after trauma, especially when the blood supply

has been affected. What a skilled Emergency Dentist provides is the best available treatment in the moment, honest prognosis, and a follow-up plan grounded in experience.

Why urgency and reassurance can coexist

The phrase “dental emergency” can alarm people, especially those who already dislike dental visits. Yet there is a useful balance to strike. Yes, accidents involving the teeth deserve prompt attention. No, panic is not helpful. The right response is urgency without chaos.

Most traumatic dental problems become easier to manage when the patient gets timely care, preserves any tooth fragments, controls bleeding, and avoids unnecessary delay. An Emergency Dentist is essential not because every accident leads to catastrophe, but because early professional management improves the odds at almost every level: pain, appearance, function, cost, and long-term tooth survival.

When people look back on these situations, they rarely regret getting seen too soon. They regret assuming it could wait. A chipped edge might have hidden a fracture. A loose tooth might have needed splinting. A knocked-out tooth might still have been saveable. The difference often comes down to acting quickly enough for expertise to matter.

That is the real value of emergency dental care after an accident. It protects more than a smile. It protects choices, comfort, and the chance to keep what nature gave you.

Smyle Dental Bakersfield
2016 E St, Bakersfield, CA 93301, United States
+16614939040

FAQ About Emergency Dentist

What counts as a dental emergency?

Severe tooth pain, facial swelling, uncontrolled bleeding, a knocked-out or displaced tooth, and significant dental trauma may need prompt assessment. Trouble breathing or rapidly increasing swelling requires urgent medical help.

What should I do if a permanent tooth is knocked out?

Handle the tooth by the crown rather than the root, keep it moist, and contact a dentist immediately. Fast treatment can improve the chance of saving the tooth.

Can an emergency dentist treat severe tooth pain the same day?

Same-day care may be available depending on the cause and schedule. The dentist will examine the area, may take digital X-rays, and recommend treatment based on the diagnosis.

Should I go to the emergency room for dental swelling?

Seek urgent medical care for trouble breathing, difficulty swallowing, rapidly spreading facial swelling, or other severe symptoms. A dentist can assess the underlying dental cause and provide appropriate follow-up care.